

# Endoscopic diagnosis of eosinophilic oesophagitis

Zhang NZ, Amanuel H. Medway Maritime Hospital, Kent UK

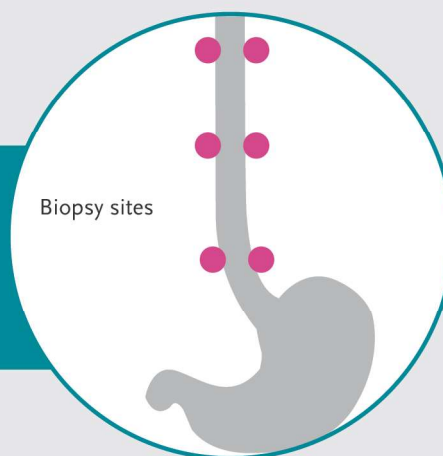
## Presented with oesophageal dysfunction

Such as dysphagia or food bolus impaction

## Diagnostic upper GI endoscopy and biopsy

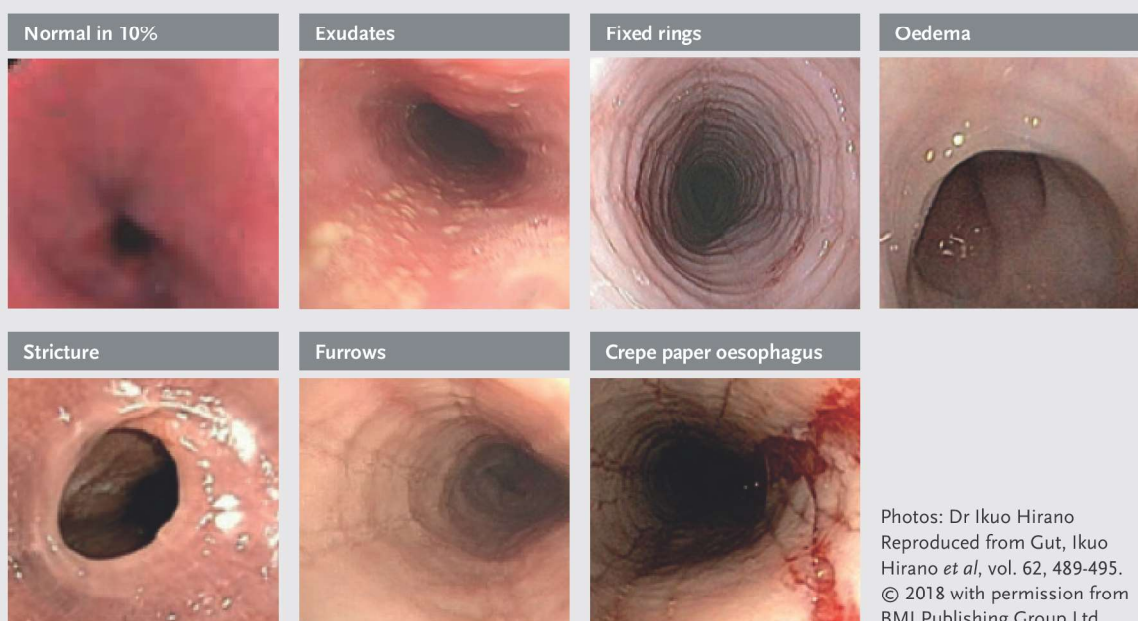
At least 6 biopsies to be obtained from the lower, mid and upper third of the oesophagus

Biopsies should be targeted to the areas of endoscopic abnormalities, mainly white exudates and longitudinal furrows, which are associated with higher peak eosinophil counts



## Diagnostic histology criteria:

oesophageal eosinophilia peak value  $\geq 15$  eos/hpf



\* Pathology request: please ask for peak eosinophil count per hpf