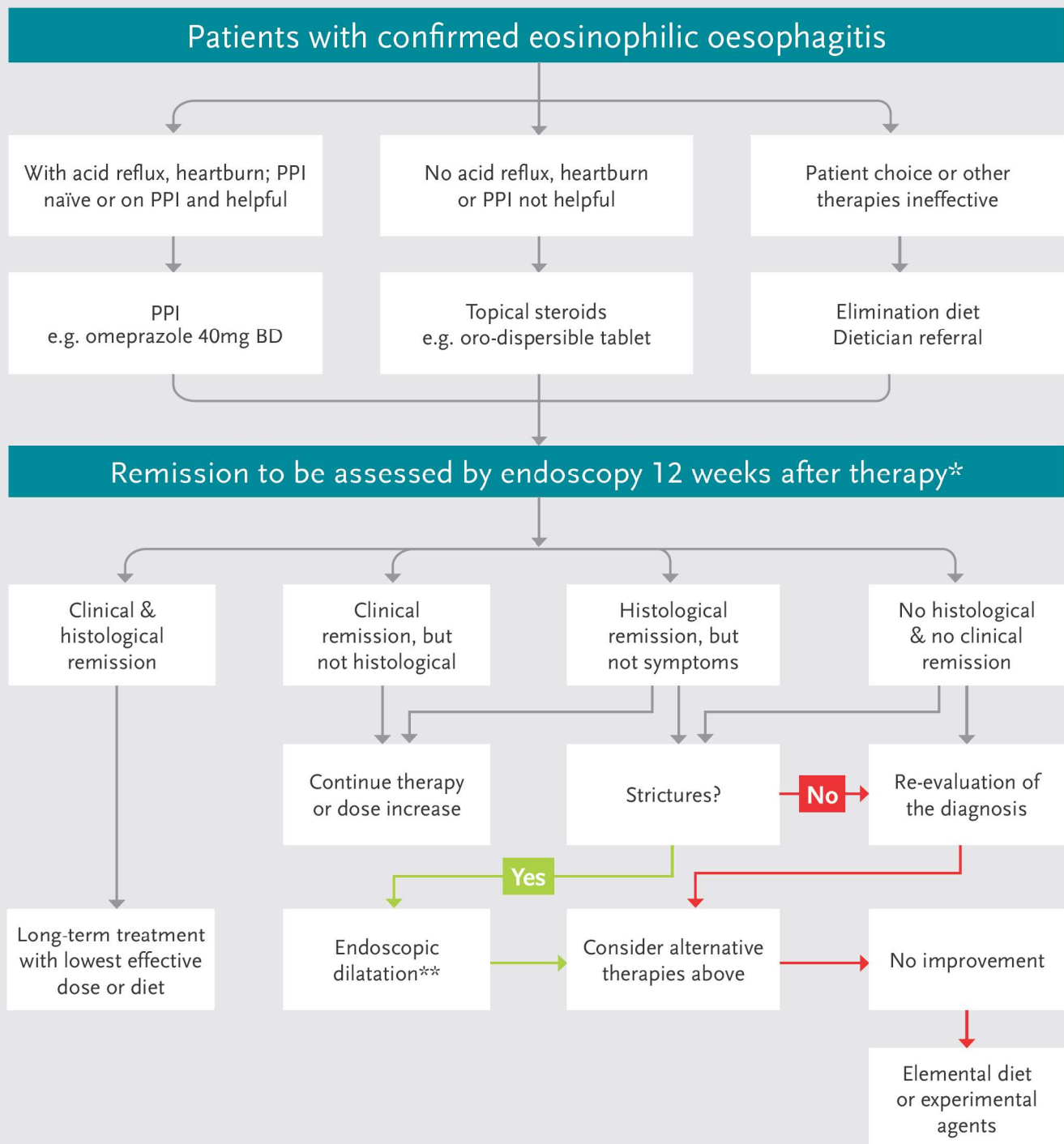


Clinical management of eosinophilic oesophagitis

Zhang NZ, Amanuel H. Medway Maritime Hospital, Kent UK



* Histology remission criteria: oesophageal eosinophilia peak value ≤ 5 eos/hpf

** After successful dilatation, then maintenance with an anti-inflammatory therapy such as topical steroid should be continued

Modified from Lucendo AJ, United Eur Gastroenterol J 2017